

# CASE REPORT

## Magnetic resonance imaging appearances of the Mirena and GyneFix intra-uterine contraceptive devices: A report of two cases

**Glen H Hall**, MRCOG, MRCPI, DFFP, *Clinical Research Fellow in Gynaecological Imaging, Centre for Magnetic Resonance Investigations, University of Hull at Hull Royal Infirmary, Hull, UK*

**Kate A Guthrie**, MRCOG, MFFP, *Consultant in Sexual and Reproductive Health, The Princes Royal Hospital, Hull, UK.*

**Lindsay W Turnbull**, MD, FRCR, *Professor of Radiology, Centre for Magnetic Resonance Investigations, University of Hull at Hull Royal Infirmary, Hull, UK*

**Correspondence:** Dr GH Hall, Centre for Magnetic Resonance Investigations, Hull Royal Infirmary, Anlaby Road, Hull, HU8 2JZ, UK. Tel: (+44) 1482 674082; Fax: (+44) 1482 320137; Email: [g.h.hall@medschool.hull.ac.uk](mailto:g.h.hall@medschool.hull.ac.uk)

(Accepted June 27<sup>th</sup>, 2000)

### Summary

We report here two cases which illustrate the magnetic resonance imaging (MRI) appearance of the Mirena levonorgestrel releasing intra-uterine system and the GyneFix copper intra-uterine contraceptive implant. The MRI appearance of these devices has not to our knowledge been reported to date, and as increasing numbers of women choose to use these devices for treatment of gynaecological conditions and contraception, it becomes increasingly important to recognise their appearance on pelvic imaging.

### Key words

GyneFix, intra-uterine contraceptive, intra-uterine system, magnetic resonance imaging, Mirena, MRI

### Key message points

- Magnetic resonance imaging (MRI) of women using any intra-uterine device (IUD) or intra-uterine system (IUS) is safe.
- MRI gives clear visualisation of the soft tissue anatomy of the uterus, and allows accurate definition of the situation of an IUS or IUD.
- MRI would be a useful test to determine if there is a uterine perforation.
- By visualising the whole pelvis MRI is a good test to find a 'lost' device.
- MRI should be considered as a second line investigation where simple ultrasound has not provided an answer to a clinical question.

### Case Reports

#### Case 1

A 36-year-old woman was referred for MRI for further assessment of a possible ovarian cyst detected on transvaginal ultrasound examination. She had a past medical history of three spontaneous vaginal deliveries of normal healthy children and 1 year previously had undergone transvaginal ultrasound scanning for investigation of heavy, painful periods. This had shown the presence of a small left ovarian cyst. Five months later a Mirena intra-uterine system was fitted both for contraception, and also in an attempt to reduce the pelvic pain and heavy menstrual bleeding (Figure 1). A repeat transvaginal ultrasound scan 2 months later showed a left-sided cystic pelvic lesion, either ovarian or tubal in origin. After insertion of the Mirena system she had daily vaginal spotting and her last normal period was 6 weeks prior to the MRI.

MRI of the pelvis was performed on an IGE 1.5T Signa Echosped MR system (IGE Medical Systems, WI) using a pelvic phased array coil for signal reception. Hyoscine butylbromide (20 mg) was administered intravenously prior to the examination to reduce bowel motion artefact. The full assessment of the pelvis included sagittal and axial T2-weighted fast spin-echo (FSE) images of the pelvis and T1-weighted spin-echo (SE) axial images. Gadolinium-diethylenetriamine penta-acetic acid (Gd-DTPA, Magnevist) was injected at a dose of 0.1 mmol/kg body weight as an intravenous bolus, and fat-saturated, post-contrast, T1-weighted SE images completed the pelvic assessment.

The left ovary demonstrated two cystic lesions, one a simple cyst, the other an endometrioma. The Mirena intra-uterine system was clearly seen as an area of lower signal intensity on both the T1- and T2-weighted images, within the endometrial cavity. The thickened hormone reservoir on the barrel of the device and the flattened wing arms of the device could be clearly seen, as indeed could the rounded ends of the arms and the retrieval threads (Figure 2).

The patient elected to continue with the intra-uterine system and to have conservative management of the endometrioma.

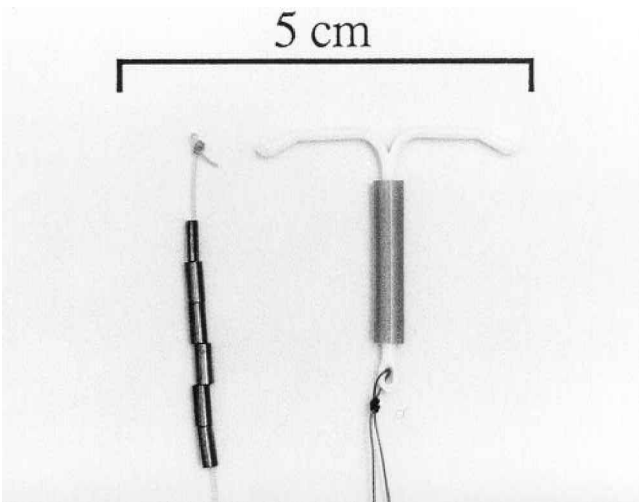
#### Case 2

The second case is that of a 23-year-old multiparous woman who had a GyneFix copper intra-uterine contraceptive implant fitted for contraceptive purposes 6 months previously (Figure 1). She complained of right-sided pelvic pain, which was worse prior to and during menstruation, and was referred for diagnostic laparoscopy. However, the procedure was abandoned due to technical difficulties prior to visualisation of the pelvic cavity. Thus she was referred for MRI assessment of the pelvis, which was performed as described for the first case.

No intra-pelvic abnormality was demonstrated to account for the patient's pain, but the GyneFix intra-uterine implant was seen on both the T1- and the T2-weighted images as a linear signal void in the centre of the endometrial cavity. The images clearly show the device to be correctly sited, anchored to the fundus in the midline (Figure 3).

In view of a normal pelvic MRI result and ongoing cyclical pain, the patient opted for ovarian down-regulation

**Figure 1** A GyneFix contraceptive implant (left) and a Mirena intra-uterine device (right)

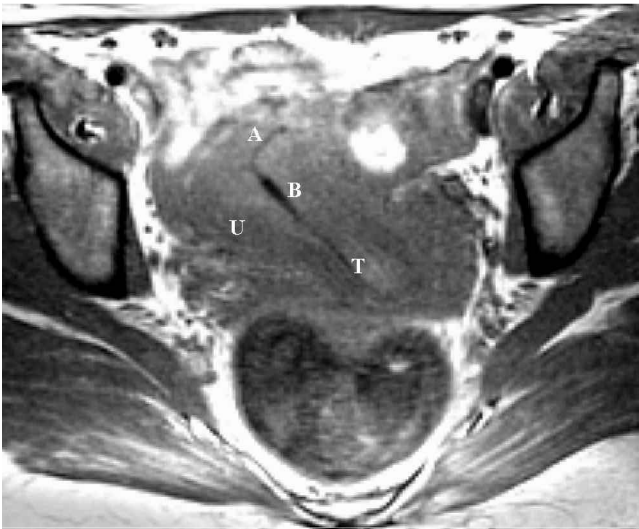

with an LHRH agonist as a diagnostic test and she remains under review at the gynaecology outpatient department, pain free.

**Discussion**

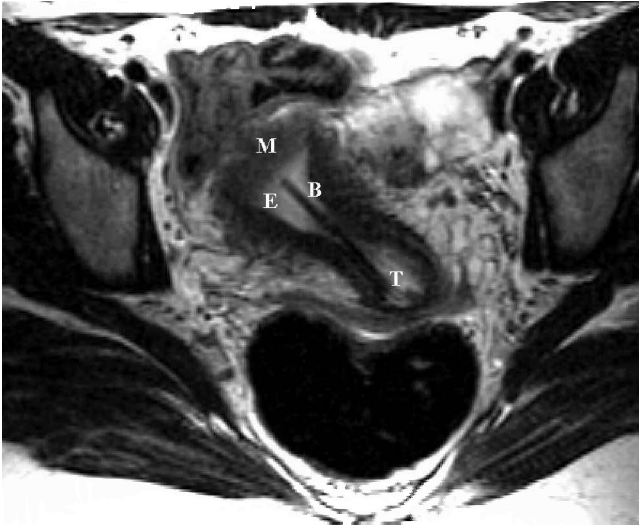
The MRI appearances of these two new intra-uterine devices have not previously been described. There is a trend in contraceptive medicine to avoid systemic administration of drugs, if possible, whilst maximising contraceptive efficacy. These two new devices closely approach these objectives. With the Mirena system we have entered a new era of intra-uterine drug delivery, with uses beyond contraceptive practice (e.g. levonorgestrel treatment of menorrhagia<sup>1-3</sup>). The Mirena device is essentially a barium

**Figure 2a** T1 weighted axial image of pelvis showing arms (A), barrel (B) and retrieval threads (T) of the Mirena system within the uterus (U)



sulphate impregnated, plastic, T framed device, the stem of which is surrounded by a reservoir of levonorgestrel enclosed in a slow release membrane. The efficacy of this device equals that of sterilisation, but yet it remains fully reversible. The GyneFix system is essentially six tubular copper beads suspended on a nylon thread that is anchored to the myometrium at the level of the fundus by a small knot. The beads lie adjacent to one another without any space intervening and so appear like a continuous piece of very narrow hollow copper tube. This system avoids drugs

**Figure 2b** T2 weighted axial image demonstrating the barrel (B) and the retrieval threads (T) of the Mirena system within the uterus. The endometrial cavity (E) appears light and is surrounded by the dark myometrium (M)

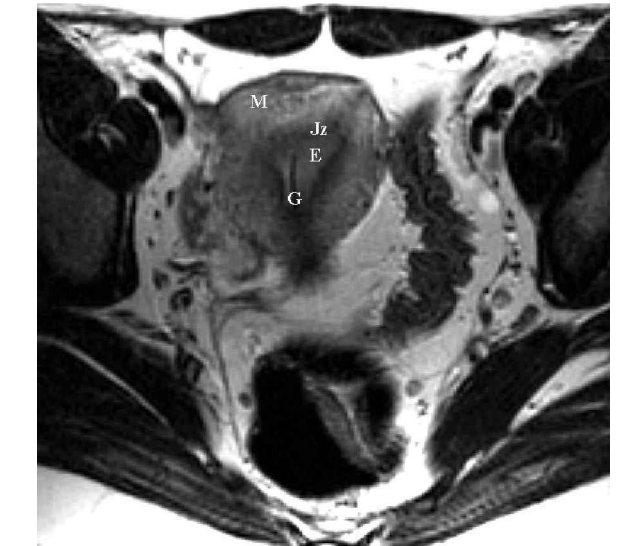


and relies on the contraceptive effects of a high surface area of copper (330 mm<sup>2</sup>). Dispensing with the plastic frame reduces the side effect of dysmenorrhoea, and anchoring the device in the myometrium obviates the risks of contraceptive failure due to slippage or expulsion.

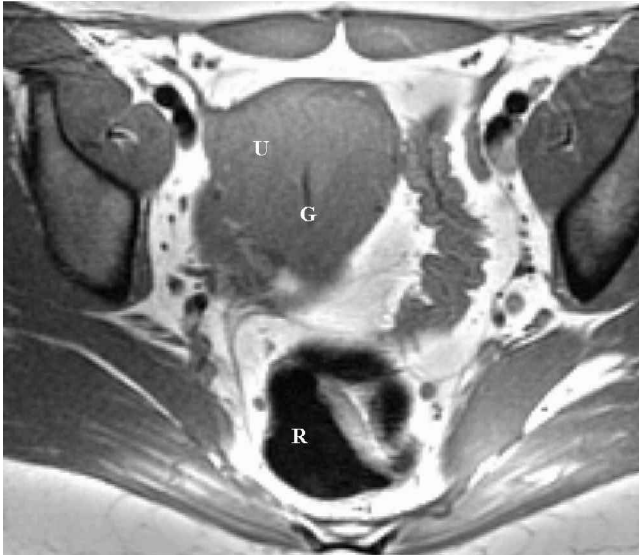These systems are being increasingly chosen by women, and the numbers of women imaged whilst wearing these devices will surely rise rapidly. It is envisaged that the above two systems will be combined and that a frameless intra-uterine route of drug delivery will become the delivery system for other drugs over the next few years.

Safety is of paramount concern in performing MR examinations, and exclusion of patients with ferromagnetic implants is necessary to prevent harm. The safety of MRI scanning in women wearing copper IUDs has been addressed in a recent publication, where it was shown that at 1.5T a CuT380A (ParaGard<sup>®</sup>) IUD showed no deflection, turning motion, or temperature change within the magnetic field.<sup>4</sup> Prior to this the Cu7 copper bearing device and the

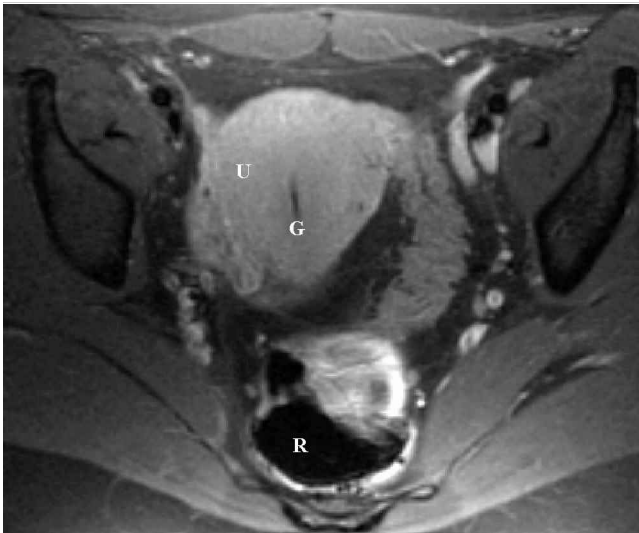
**Figure 3a** T2 weighted axial image demonstrating the dark copper beads of the GyneFix system (G) with the light endometrial cavity (E). The tip of the device is seen to abut the darker junctional zone of the myometrium (Jz) where the knot is anchored, and this is surrounded by the lighter outer myometrium (M).



**Figure 3b** T1 weighted axial image demonstrating the dark GyneFix system (G) within the uterus (U). Note the zonal anatomy of the uterus is not seen on a T1 weighted image. The rectum (R) is seen posteriorly.



**Figure 3c** Post-contrast fat-suppressed T1 weighted axial image demonstrating the GyneFix system (G) within the uterus (U). The rectum (R) is seen posteriorly.



inert Lippes Loop had been examined in the magnetic field, and no adverse effects reported.<sup>5</sup> The authors concluded that screening patients for the presence of an IUD before MRI or removing an IUD solely for the purposes of an MRI scan were unnecessary.

Plain film x-ray and ultrasound are both useful first line techniques for the location of ‘lost’ intra-uterine devices, and these techniques are both cheap and easily accessible. Indeed some clinicians advocate the routine use of transvaginal sonography in gynaecology and family planning outpatient clinics to check the intra-uterine location of an IUD.<sup>6</sup> However, IUDs have been described perforating the bladder<sup>7</sup> and the rectum<sup>8</sup> as well as sitting in the Pouch of Douglas and peritoneal cavity. The inherent safety, multiplanar capabilities and soft tissue resolution in women of reproductive years, make MRI a valuable technique to consider when evaluating a woman with a misplaced intra-uterine device.

**Acknowledgement**

The centre of Magnetic Resonance Investigations at the University of Hull is supported by Yorkshire Cancer Research.

**Statements on funding and competing interests**

Funding. None.

Competing interests. None.

**References**

- 1 Irvine GA, Cameron IT. Medical management of dysfunctional uterine bleeding. *Best Practice and Research in Clinical Obstetrics and Gynaecology* 1999; **13**(2): 189–202.
- 2 Irvine GA, Campbell-Brown MB, Lumsden MA, et al. Randomised comparative trial of the levonorgestrel intrauterine system and norethisterone for treatment of idiopathic menorrhagia. *British Journal of Obstetrics and Gynaecology* 1998; **105**(6): 592–598.
- 3 Lahteeninaki P, Haukkamaa M, Puolakka J, et al. Open randomised study of the use of levonorgestrel releasing intrauterine system as alternative to hysterectomy. *British Medical Journal* 1998; **316**(7138): 1122–126.
- 4 Pasquale SA, Russer TJ, Foldes R, et al. Lack of interaction between magnetic resonance imaging and the Copper-T380A IUD. *Contraception* 1997; **55**(3): 169–173.
- 5 Mark AS, Hricak H. Intrauterine contraceptive devices: MR imaging. *Radiology* 1987; 311–314.
- 6 Granberg S, Bunsden P, Bourne TH, et al. The use of transvaginal ultrasonography compared to routine gynecological examination to check the location of an intrauterine contraceptive device. *Ultrasound in Obstetrics and Gynaecology* 1994; **4**(4): 316–319.
- 7 Kriplani A, Banerjee N, Hemal AK, et al. Partial perforation of the bladder by multiloop. *Australian and New Zealand Journal of Obstetrics and Gynaecology* 1999; **39**(1): 133–135.
- 8 Banerjee N, Kriplani A, Roy KK, et al. Retrieval of lost Copper-T from the rectum. *European Journal of Obstetrics Gynaecology and Reproductive Biology* 1998; **79**(2): 211–212.