

CASE REPORT

Caesarean section scar ectopic pregnancy following postcoital contraception

Laura Fabunmi, MB BS, MRCOG, *Specialist Registrar in Obstetrics and Gynaecology, Queen Elizabeth Hospital, London, UK;*
Nigel Perks, FRCOG, *Consultant Obstetrician and Gynaecologist, Queen Elizabeth Hospital, London, UK*

Correspondence: Dr Laura Fabunmi. E-mail: Laufab@aol.com

(Accepted 10th March 2002)

The Journal of Family Planning and Reproductive Health Care 2002; **28**(3): 155-156

Abstract

This is believed to be the first reported case of an ectopic pregnancy following failed progestogen-only emergency contraception. The ectopic pregnancy was at the site of a previous caesarean section scar and was managed conservatively.

Case report

A 38-year-old multiparous woman with two previous caesarean sections was reviewed in the early pregnancy unit with intermittent vaginal bleeding and a positive pregnancy test following progestogen-only emergency contraception. A transvaginal ultrasound scan revealed an empty uterus and serum beta-human chorionic gonadotrophin (β -hCG) was 625 mIU/ml.

The patient was reviewed 2 weeks later with a 1-day history of left iliac fossa pain and 5 days of moderate vaginal bleeding. A transvaginal ultrasound scan showed an empty uterine cavity and a 2.5 cm mass in the anterior uterine wall reported as a probable degenerating fibroid. The repeat serum β -hCG was raised at 10 000 mIU/ml.

Clinically the patient was haemodynamically stable and was admitted for a diagnostic laparoscopy, which revealed normal-looking tubes, a fibroid uterus including anterior and posterior pedunculated fibroids, and a mass on the left ovary. At laparotomy a left ovarian cystectomy was performed which was later diagnosed as a benign dermoid cyst. There was no blood in the peritoneal cavity and no visible evidence of an ectopic pregnancy.

Figure 1 Transvaginal sonogram showing the intramural pregnancy indicated by the arrow. U, Uterus; C, cervix

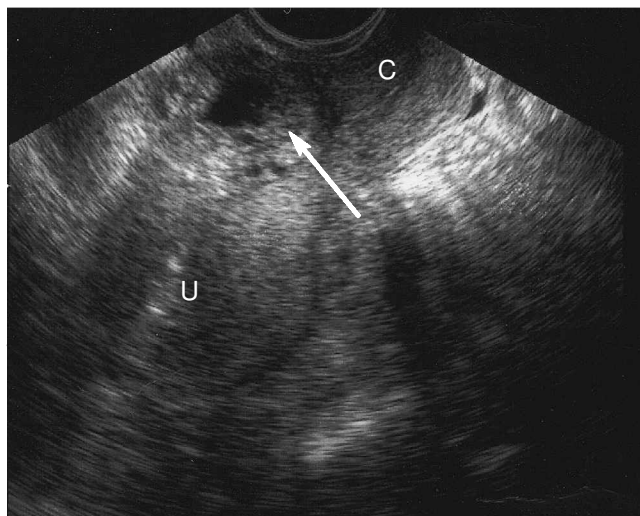
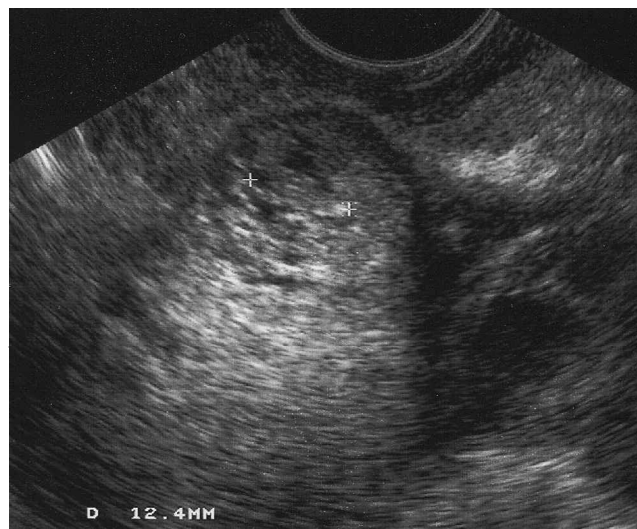


Figure 2 Magnified view of the gestational sac showing the fetus indicated by the markers



Postoperative recovery was uneventful, however the serum β -hCG levels rose and reached a plateau. A repeat transvaginal scan showed a live ectopic pregnancy in the anterior uterine wall at the level of the previous uterine scar. (Figures 1 and 2).

The patient was transferred to a tertiary unit 6 days postoperatively where she had local injection of methotrexate and potassium chloride into the gestational sac under ultrasound guidance.

Over the course of 8 weeks serum β -hCG and serum progesterone gradually fell. The patient had minimal vaginal bleeding until 6 weeks post-treatment when she had an episode of heavy vaginal bleeding which required an evacuation of the uterine cavity and blood transfusion. She had minimal bleeding for a further 4 weeks and then had two normal periods. An ultrasound scan confirmed resolution of the ectopic pregnancy and serum hGG and progesterone levels were not significant.

Discussion

Ectopic pregnancy following failed postcoital contraception is rare and only tubal pregnancies have been reported in the literature. We believe this is the first reported case of a non-tubal ectopic pregnancy following postcoital contraception.

Reported cases of ectopic pregnancy have been with the Yuzpe regime, diethylstilboestrol or stilboestrol.^{1,2} There have been no recorded cases in the medical literature of ectopic pregnancy after failed progestogen-only emergency contraception.

The present case highlights the importance of follow-up after emergency contraception. Women should be encouraged to report any unusual bleeding even if they think they have had a period. A high suspicion of ectopic pregnancy is usually entertained if there is a history of previous tubal disease or surgery, however risk factors for non-tubal ectopic pregnancies such as previous caesarean section should be considered.

It is important to search carefully for the site of an ectopic pregnancy if the laparoscopy is negative, particularly if β -hCG levels are high. The history of a previous caesarean section and the possibility of an 'intramural fibroid' might have alerted us to the diagnosis. Furthermore, the presence of unrelated pathology such as an ovarian cyst or presence of fibroids may distract the operator from establishing the correct diagnosis as in the present case where the ovarian cyst was a 'red herring'.

If the diagnosis is unclear on ultrasound, magnetic resonance imaging (MRI) may be useful. Godin et al. described the first case of an ectopic pregnancy in a previous caesarean section scar diagnosed with vaginal echography and MRI.³

Intramural pregnancies are very rare and there are only a few recorded cases in the literature. Complications may be disastrous due to significant haemorrhage and uterine rupture mainly due to late diagnosis. The pathology is thought to be due to the conceptus entering the myometrium through a microscopic dehiscence tract in the caesarean section scar.³

Earlier cases were treated with hysterectomy but more conservative surgical approaches have now been tried such as hysterotomy and laparoscopic excision.⁴

Medical treatment of tubal ectopic pregnancy with methotrexate is now well established and has become a standard option in appropriately selected patients.⁵ There are no large series reports of the management of intramural pregnancies in the literature. However, case reviews of the management of other non-tubal pregnancies, i.e. cornual and cervical ectopic pregnancies, have shown successful outcome with methotrexate either by systemic or direct injection.⁶

The present case illustrates the successful use of methotrexate by direct injection into the gestational sac. It should be noted, however, that patients still require close follow-up due to possible complications such as heavy bleeding as seen in the present case.

Statements on funding and competing interests


Funding. None declared.

Competing interests. None declared.

References

- Nielsen CL, Miller L. Ectopic pregnancy following emergency contraceptive administration *Contraception* 2000; **62**(5): 275–276.
- Kubba AA, Guillebaud J. Case of ectopic pregnancy after postcoital contraception with ethinyloestradiol levonorgestrel *BMJ* 1983; **287**(6402): 1343–1344.
- Godin PA, Bassil S, Donnez J. An ectopic pregnancy developing in a previous caesarean section scar. *Fertil Steril* 1997; **67**(2): 398–400.
- Lai YM, Lee JD, Lee CL, et al. An ectopic pregnancy embedded in the myometrium of a previous caesarean section scar. *Acta Obstet Gynecol Scand* 1995; **74**(7): 573–576.
- Yao M, Tulandi T. Surgical and medical management of tubal and non tubal pregnancies. *Curr Opin Obstet Gynaecol* 1998; **10**(5): 371–374.
- Buster JE, Heard MJ. Current issues in medical management of ectopic pregnancy. *Curr Opin Obstet Gynaecol* 2000; **12**(6): 525–527.

herpes simplex can be more than a physical problem . . .



The Herpes Viruses Association helpline supplies information to patients and medical practitioners. Helpline volunteers who have the virus, including 'pregnancy helpliners' who have given birth, are trained to counsel and advise.

* "Patients with genital herpes suffer considerable psychological morbidity and the fact that they are able to receive very sophisticated and experienced counselling . . . has been extremely useful in helping them deal with their condition. The HVA has fulfilled this role admirably over the years . . ."

Prof. M W Adler MD FRCP FFPHM, UCL Medical School, London

* "Nobody does what they do, filling an important niche."

Dr Paul Simmons MB FRCP, St Bartholomew's Hospital, London

helpline
020 7609 9061

For leaflets, patient information cards or posters, write or send e-mail to:
HVA, 41 North Road, London N7 9DP
marian@herpes.org.uk

We often hear this comment
"I wish I'd been told about you years ago"

**PREGNANCY CRISIS
AND
POST ABORTION**
0800 028 2228
www.pregnancy.org.uk
CarE LINE

Offering pregnancy and
post abortion help to anyone
facing an unwanted pregnancy
or struggling after an abortion.

Call 0800 028 2228
for free confidential support
and information.

or visit our website for
more information

www.pregnancy.org.uk