

CASE REPORTS

Intravesical migration of a GyneFix® intrauterine device

O S Eskandar, DGO, MRCOG, *Staff Grade in Obstetrics and Gynaecology*; **S D Eckford**, MRCOG, FRCSEd, *Consultant, Department of Obstetrics and Gynaecology, North Devon District Hospital, Barnstaple, UK*

Correspondence: Mr O Eskandar, Department of Obstetrics and Gynaecology, North Devon District Hospital, Barnstaple, Devon EX31 4JB, UK. E-mail: osamaeskandar@hotmail.com

(Accepted 26 April 2003)

Journal of Family Planning and Reproductive Health Care 2003; **29**(4): 237–238

Abstract

A case of intravesical migration of a GyneFix® intrauterine device (IUD) is described, in which the patient presented with supra-pubic pain and urinary symptoms. The diagnosis was made 34 months after the insertion of the IUD, by ultrasound scan. The GyneFix was removed endoscopically. A description of the GyneFix device, the possible adverse effects and incidences of its complications, the importance of post-insertion follow-up, and the need for awareness of the possibility of intravesical migration are discussed.

Case report

A 23-year-old nulliparous woman was referred by her general practitioner (GP) with an 18-month history of suprapubic pain. She had been fitted with a GyneFix® intrauterine device (IUD) in June 1999 (34 months previously).

The IUD was fitted uneventfully using a standard technique. Sixteen months post-fitting the patient developed recurrent strangury and urinary frequency, which was refractory to multiple courses of empirical antibiotics. The suprapubic pain worsened over the following months, especially post-micturition. Pelvic examination was normal but failed to locate the threads of the GyneFix. A pelvic ultrasound scan suggested that the coil was lying free in the bladder. The patient underwent cystoscopic and endoscopic removal of the GyneFix; at that time the GyneFix IUD was found adherent to the right lateral aspect of the trigone of the bladder. It was markedly calcified but was removed easily by the endoscopic route. The patient made an uneventful recovery. At the 6-week post-operative review she was asymptomatic.

Discussion

The GyneFix is a 'frameless' IUD comprising six copper sleeves, each 5 mm long and 2.2 mm in diameter, threaded onto a length of semi-rigid suture material. The device has undergone 10 years of testing and several modifications to its inserter and anchoring mechanisms.^{1,2} The upper extremity of the thread contains a knot that is inserted using a needle at a depth of 1 cm into the fundal myometrium in order to anchor the device into the uterine muscle. On account of its frameless design, flexibility and minimal presence in the uterine cavity, the GyneFix is associated with few expulsions (2–8%). Such expulsions depend on the duration of use, and the frequency of expulsion is particularly low among nulliparous women.^{2,3} The device has a high continuation rate at 1 year (85–90%) because there are few removals on account of bleeding and/or pain.³ The reported failure rate from long-term clinical studies is 0.5 at 3 years.

No uterine perforations occurred in approximately 5000 insertions of GyneFix, FlexiGard or TCu380A® in two published studies that covered 3 years.⁴ According to the manufacturer, perforations occur rarely with GyneFix (around

1 in every 1000 insertions).⁴ This rate is similar to that reported for other IUDs (1.3 in every 1000 insertions).⁴ An incorrect insertion technique may increase the risk of perforation.⁵ Late perforations and intraperitoneal location have also been reported. These perforations occurred between 11 days and 4 months after insertion of the GyneFix device.^{6–8} The present case represents a unique delayed uterine perforation and intravesical migration after perforation or perforation at the time of insertion. Intravesical migration of a GyneFix IUD has not been reported previously.

The fact that the GyneFix was found in a calcified state suggests that it had been present in the bladder for a long time. It is difficult to know exactly how long the IUD had been present in the bladder, especially as the patient did not manage to conceive after the insertion of the GyneFix. However, the patient's symptoms started 16 months after insertion of the IUD. A frameless device anchored in the myometrium might erode through more easily than a framed device.⁷ However, the device is inserted in the fundal myometrium, which is not in a direct anatomical relationship to the bladder. This might indicate a perforation and subsequent migration into the bladder.

The present case demonstrates not only the importance of checking the IUD threads but also the importance of ultrasound scan follow-up including long-term follow-up to check the distance between the peritoneal surface of the uterus and the first copper sleeve. (If the distance is <10 mm or >20 mm this may indicate the need for the removal of the GyneFix device.) This may have an adverse affect on the attractiveness of the method to potential users.^{7,8} Although it is very rare, the possibility of late perforation and migration highlights the importance of the routine regular post-insertion check-up, particularly for frameless IUDs.

Finally, de novo lower urinary tract symptoms in a woman with an IUD in situ may alert the clinician to the possibility of total or partial migration of the device into the bladder.

Statements on funding and competing interests

Funding. None identified.

Competing interests. None identified.

References

- Wildemeersch D. The FlexiGard® 330. In: Bardin CW, Mishell DR Jr (eds), *Proceedings from the Fourth International Conference on IUDs*. London: Butterworth-Heinemann, 1994; 273–283.
- Wildemeersch D, Van Kets H, Vrijens M, et al. Intrauterine contraception in adolescent women. The GyneFix intrauterine implant. In: Creatas G, Mastorakos G, Chrousos GP (eds), *Adolescent gynecology and endocrinology: basic and clinical aspects*. New York, NY: The New York Academy of Sciences, 1997; 440–450.
- International Study Group on Intrauterine Drug Delivery. The GyneFix® implants systems for interval, postabortal and postpartum contraception: a significant advance in long-term reversible contraception. *Eur J Contracept Reprod Health Care* 1997; **2**: 1–13.
- Frameless intra-uterine contraceptive device (GyneFix). *Drug Ther Bull* 2002; **40**: 22.
- Wildemeersch D. Important notice. *Br J Fam Plann* 2000; **26**: 88.

- 6 Al-Kamil RK. Perforation of the uterus by the GyneFix intrauterine contraceptive device. *Int J Clin Pract* 2000; **54**(2): 128–129.
- 7 Gandhi JD, Whitmore J, Iskander MN. Uterine perforation by GyneFix frameless IUD: two case reports. *J Fam Plann Reprod*

Health Care 2001; **27**: 153–154.

- 8 Vekemans M, Verougstraete A. Late uterine perforation with an anchored IUD, the GyneFix. A case report. *Contraception* 1999; **60**: 55–56.

Spontaneous snapping of an Implanon® in two halves in situ

Anjali Agrawal, MRCOG, DFFP, *Staff Physician in Family Planning*; **Christine Robinson**, MRCOG, MFFP, *Consultant in Family Planning and Sexual Health, The Lodge, Luton, UK*

Correspondence: Dr Anjali Agrawal, The Lodge, 4 George Street West, Luton LU1 2BJ, UK. E-mail: anjaliagr awala@hotmail.com

(Accepted 4 August 2003)

Journal of Family Planning and Reproductive Health Care 2003; **29**(4): 238

Abstract

A 30-year-old woman presented at our family planning clinic for Implanon® removal and reinsertion. At the time of presentation the patient's weight was 148 kg. The Implanon was fitted in July 2000 (i.e. 35 months previously) when her weight was 138.5 kg. The patient was very happy with the contraceptive method. She was aware that her Implanon had snapped in half about 2 months ago. There was no aggravating factor such as weightlifting associated with this incidence.

Case report

A 30-year-old woman presented at our family planning clinic (FPC) on 28 May 2003. She attended for Implanon® removal and reinsertion. At the time of presentation the patient's weight was 148 kg.

She had noticed that her Implanon had snapped in half approximately 2 months ago. There had been no associated trauma to her arm or aggravating factor such as weightlifting. There was no change in the patient's symptomatology except that her bleeding was heavier than before the Implanon broke.

The Implanon was fitted in July 2000 (i.e. 35 months previously) in the non-dominant arm. At that time the patient's weight was 138.5 kg. She did not attend for follow-up, despite the fact that she had been requested to, because she did not have any problems. She was very happy with the contraceptive method.

Her obstetric history revealed she was para 2+0; the first child was born in 1996 by spontaneous vaginal delivery at term and second was born in 1998 by emergency Caesarean section for breech presentation.

Her menarche was at age 15 years. Prior to Implanon insertion her menstrual cycles were 5–6 days/3–8 weeks. After the insertion her periods became very light. She had used combined pills and minipills in the past. She had no medical problems except that she was overweight. She was a non-smoker.

The Implanon was removed under 2% lidocaine infiltration with two separate incisions since there was a gap between the two halves. A new Implanon was inserted at the same time, and the patient was advised to return in 6 weeks' time for follow-up. She was also advised to have the replacement Implanon removed in 2.5 years' time since she was overweight.

Discussion

To the best of our knowledge this is the first case of an Implanon snapping in two halves spontaneously in situ. The only previous case reported in the literature is one in which an Implanon had fractured halfway across its width.¹ In that particular case the Implanon was broken during a game of 'rough and tumble' and since that time the patient had begun bleeding heavily for 3 weeks every month. After the removal of the broken Implanon and reinsertion of a new one the bleeding settled.

In contrast to this reported case, in the present case the Implanon snapped spontaneously in two halves without the presence of any aggravating factor. The breakage of the Implanon did not unduly concern the patient, and she attended the FPC 2 months later because her Implanon was due to be changed. It is difficult to say whether the change in bleeding pattern was due to the breakage of the Implanon or because the Implanon was due to be changed. An earlier review of clinical studies² reported three broken implants in 1716 insertions. However, these authors did not mention whether the Implanon devices were broken prior to, or during, the removal process. Finally, we confirmed with the manufacturer's medical information department that there have been no other reported cases of a broken Implanon.

Acknowledgement

This case report is published with the kind permission of the patient concerned.

Statements on funding and competing interests

Funding. None identified.

Competing interests. None identified.

References

- Pickard S, Bacon L. Persistent vaginal bleeding in a patient with a broken Implanon®. *J Fam Plann Reprod Health Care* 2002; **28**: 207–208.
- Edwards JE, Moore A. Implanon: a review of clinical studies. *Br J Fam Plann* 1999; **24**: 3–16.

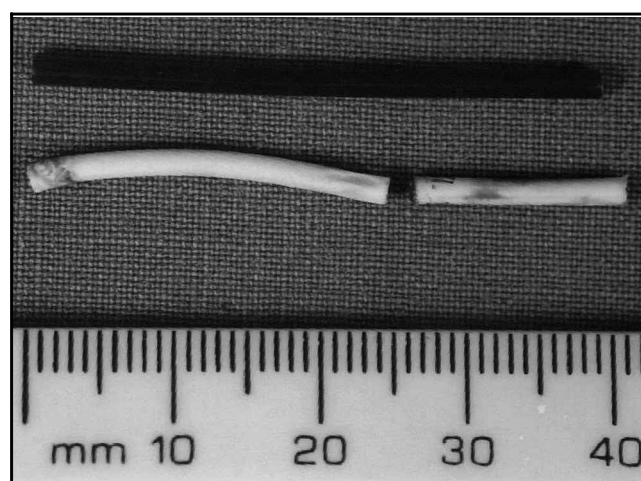


Figure 1 The broken Implanon as compared with a model Implanon