

## Sweet's syndrome and a Mirena<sup>®</sup> intrauterine system

**Matthew Hamill**, MRCP (UK), DTM&H, SpR GUM, Department of Genitourinary Medicine, St Mary's Hospital, Praed Street, London, UK; **Jonathan Bowling**, MB ChB, MRCP (UK), SpR Dermatology, Department of Dermatology, Chelsea and Westminster Hospital, London, UK; **F Vega-Lopez**, MSc, PhD, Consultant Dermatologist, Department of Dermatology, The Middlesex Hospital, UCLH, London, UK

**Correspondence:** Dr Matthew Hamill, Department of Genitourinary Medicine, St Mary's Hospital, Praed Street, London W2 1NY, UK. E-mail: matthew.hamill@st-marys.nhs.uk

(Accepted 3 October 2003)

*Journal of Family Planning and Reproductive Health Care* 2004; **30**(2): 115–116

### Abstract

A woman fitted with a Mirena<sup>®</sup> intrauterine system (IUS) for menorrhagia presented with a short history of fever and progressive skin lesions. Histological examination of a skin biopsy was compatible with the clinical diagnosis of Sweet's syndrome. Treatment was with topical and oral steroids, however the condition relapsed on reduction of the steroid dose. Symptoms finally resolved on removal of the IUS and the patient remained symptom free at 9-month follow-up. There have been previous reports of Sweet's syndrome in association with hormonal contraceptives, however this is believed to be the first reported case in association with a Mirena IUS.

### Introduction

Acute febrile neutropenic dermatosis or Sweet's syndrome is associated with a wide range of conditions. It has recently been reported to be associated with a variety of hormonal influences. We describe a case of relapsing Sweet's syndrome temporally associated with a Mirena<sup>®</sup> intrauterine system (IUS) that resolved on IUS removal. This is the first such case reported in the literature. We feel that this association has implications for clinical practice.

### Case report

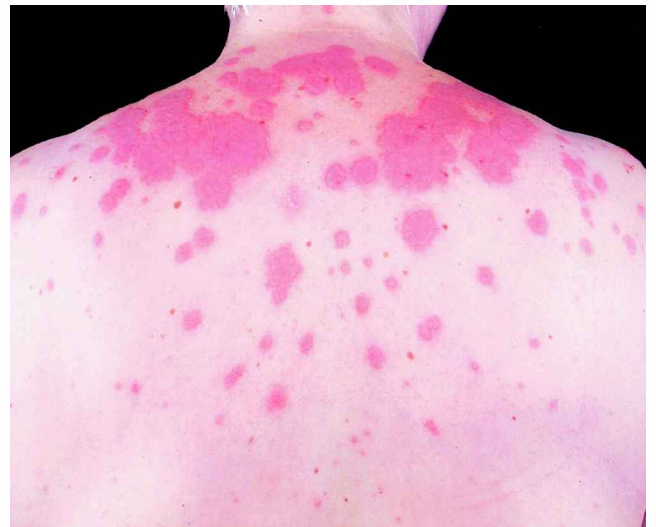A 54-year-old woman was referred to the dermatology outpatient clinic with an 8-day history of fever and a rash affecting her back, arms, legs, face, hands and feet.

Past medical history included menorrhagia for which the patient underwent a polypectomy for benign uterine polyps 1 month prior to presentation. Post-polypectomy she had a Mirena IUS inserted. She gave no history of pharyngitis, arthralgia or other mucosal involvement, and was taking no regular medication.

Initial examination revealed a fever of 37.7°C and multiple annular, indurated nodules coalescing over her shoulders and wrists. No other systemic signs were present (Figure 1).

Initial laboratory investigations demonstrated a C-reactive protein of 372 (range, 0–5) mg/l, mildly raised alkaline phosphatase of 125 (32–104) U/l and alanine aminotransferase of 52 (7–49) U/l. The full blood count showed a raised total white cell count and neutrophilia at  $10.1 (3.0–10.0) \times 10^9/l$  and  $8.10 (2.0–7.5) \times 10^9/l$ , respectively. The haemoglobin was 12.6 (11.5–15.5) g/dl with a platelet count of  $239 (150–400) \times 10^9/l$ . Atypical pneumonia serology, serum angiotensin-converting enzyme and autoantibody screen were negative.

Histology from skin biopsy revealed an acute inflammatory infiltrate in the upper dermis with neutrophils and leucocytoclasia; lymphocytes, plasma cells and eosinophils were present. There was perivascular chronic inflammatory cell infiltrate. The



**Figure 1** The typical skin lesions of Sweet's syndrome.

features were consistent with a diagnosis of Sweet's syndrome (Figure 2).

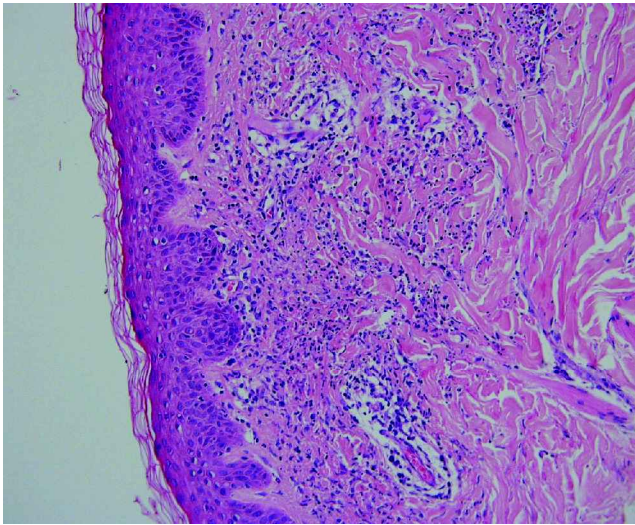
Initial management consisted of oral corticosteroids (prednisolone 60 mg daily) and topical clobetasol propionate cream. The patient was reviewed 2 weeks later and found to have no new lesions and the prednisolone dose was reduced. She remained well for 5 weeks on a maintenance dose of 5 mg prednisolone daily before re-attending with a 1-week history of recurrent lesions on both upper arms and hands. Her prednisolone dose was increased to 60 mg daily.

Her IUS was removed 2 months after initial dermatological presentation and 3 months after initial insertion. After removal of the IUS the prednisolone dose was decreased to 5 mg daily for 2 weeks then discontinued. Six weeks after stopping corticosteroid treatment the patient was well with no new skin lesions. She was discharged with no further skin symptoms 9 months after initial dermatological presentation. This case report clearly provides temporal and clinical evidence of the correlation of the Mirena IUS and Sweet's syndrome.

### Discussion

Robert Douglas Sweet first described acute febrile neutrophilic dermatosis or Sweet's syndrome in 1964.<sup>1</sup> Sweet's syndrome consists of a constellation of tender, erythematous, cutaneous plaques, fever, malaise and neutrophilic leucocytosis.

Classical Sweet's syndrome affects the face, neck, chest, back and extremities and is predominately described in middle-aged women following respiratory or gastrointestinal infection. The plaques may vary in size



**Figure 2** Histological section of skin biopsy showing characteristic neutrophilic infiltrate in the upper dermis.

from less than a centimetre to several centimetres in diameter. Plaques can vary in appearance from pseudopustules to blisters. They tend to be red with a paler yellow/white centre in common with the target lesions of erythema multiforme.

Sweet's syndrome has been described in association with a large number of conditions including malignancy (haematological and solid tumour),<sup>2</sup> infection (bacterial, fungal and protozoal), inflammatory and rheumatological conditions and pregnancy.<sup>3</sup> It has also been described affecting eyes, joints, oral mucosa and internal organs.

The characteristic skin histology is of a dense dermal infiltrate of neutrophils and classically there is vasodilatation and erythrocyte extravasation. Inflammatory cells demonstrate a band-like infiltration in the papillary dermis.

The typical clinical response to corticosteroid therapy is dramatic. Other therapeutic approaches have been with dapsone, cyclosporin and colchicine.

The incidence of Sweet's syndrome ranges from an annual incidence of 2.7 in 1 000 000 in Scotland<sup>4</sup> to 1 in 250 in a Sri Lankan outpatient setting.<sup>5</sup> Incidence figures may rise as awareness of Sweet's syndrome increases.

The Mirena IUS has as its active ingredient levonorgestrel 52 mg with a release rate of 20 µg per 24 hours. Its therapeutic indications are contraception and idiopathic menorrhagia and it is effective for 5 years. Contraindications include genital infections and active or previous ischaemic or cerebrovascular disease. No previous associations with Sweet's syndrome have been described.

Predilection to Sweet's syndrome and associated disorders such as oestrogen and progesterone dermatosis, erythema nodosum and pyoderma gangrenosum for female patients may suggest a hormonal influence on pathogenesis. Sweet's syndrome has also been linked to the oral contraceptive pill.<sup>6</sup> The association that we found with the Mirena IUS adds weight to this hypothesis. It also serves to highlight the importance of detailed clinical history taking in patients with dermatological signs, particularly with regard to hormonal contraception and implants/prostheses.

#### Acknowledgement

The author wishes to thank Dr N Etesami of the Department of Pathology, UCLH, London, UK for providing the histology image and the kind permission of the patient for allowing publication of the case report.

#### Statements on funding and competing interests

*Funding.* None identified.

*Competing interests.* None identified.

#### References

- 1 Sweet RD. An acute febrile neutrophilic dermatosis. *Br J Dermatol* 1964; **74**: 349–356.
- 2 Bourke JF, Keohane S, Kemmett D, et al. Sweet's syndrome and malignancy in the UK. *Br J Dermatol* 1997; **137**: 609–613.
- 3 Cohen PR. Pregnancy associated Sweet's syndrome: world literature review. *Obstet Gynecol Surv* 1993; **48**: 584–587.
- 4 Kemmett D, Hunter JAA. Sweet's syndrome: a clinicopathological review of 29 cases. *J Am Acad Dermatol* 1990; **23**: 503–507.
- 5 Gunawardena DA, Gunawardena KA, Ratnayaka MRS, et al. The clinical spectrum of Sweet's syndrome; a report of 18 cases. *Br J Dermatol* 1975; **92**: 363–373.
- 6 Saez M, Garcia-Bustinduy M, Noda A, et al. Sweet's syndrome induced by oral contraceptive. *Dermatology* 2002; **204**: 84.

## TRAINING & EDUCATION

### The development of an intrauterine device/intrauterine system computer-assisted learning package

**Sarah A Hughes**, MFFP, MSc Clin Ed, *Consultant in Contraception and Sexual Health, Nottingham City Primary Care Trust, Nottingham, UK*

**Correspondence:** Dr Sarah Hughes, Centre for Contraception and Sexual Health, Victoria Health Centre, Glasshouse Street, Nottingham NG1 3LW, UK. E-mail: sarah.hughes@nottinghamcity-pct.nhs.uk

(Accepted 11 February 2004)

*Journal of Family Planning and Reproductive Health Care* 2004; **30**(2): 116–117

#### Introduction

Attached to this edition of the Journal is a CD-ROM computer-assisted learning (CAL) package to support doctors and nurses who are training to fit intrauterine devices/intrauterine system (IUD/IUS) and provide an update for doctors and nurses in line with Faculty of Family Planning and Reproductive Health Care

(FFPRHC) and Royal College of Nursing (RCN) requirements.

This package has been produced to coincide with the release of the Clinical Effectiveness Unit (CEU) IUD and IUS Guidance published in the January and April 2004 issues of the Journal, respectively.<sup>1,2</sup> The content has been developed to align with this Guidance. The package is