

Difficult IUD insertions

I read with interest Dr Isabel Draper's letter¹ regarding difficult intrauterine device (IUD) insertions published in the January 2008 issue of this Journal. I agree with Dr Draper's views and would like to share my experience on this subject.

I am an instructing doctor and do two IUD/intrauterine system (IUS) training clinics every week. One training clinic is at The Palatine Centre in Manchester and the other is a Gynaecology Tier 2 clinic in Stockport with facilities for on-site ultrasound scanning for difficult IUD/IUS insertions/removals. On an average five patients are seen in each clinic for IUD/IUS insertions.

Nearly 30% of patients I see are under the age of 25 years and nulliparous. In my experience I have found that insertion of TT380 Slimline®, TCu380®, QuickLoad® or T-Safe 380A®, which are current recommended gold standards, can be at times difficult and painful to insert in this group of patients. I agree with the author's comments that insertion of the IUS can also be challenging in this group of women.

I find the following methods helpful in reducing the discomfort associated with IUD/IUS insertions.

- 1 Injection of local anaesthetic directly into the cervix (intracervical block) at the 3, 6, 9 and 12 o'clock position is very effective. A 27-gauge dental syringe is used to inject 3% Mepivacaine (Scandonest®) or Articaine® with adrenaline (Septanest®), which is available in cartridges. In order to divert the women's attention I usually ask the patient to cough at the time of injection.
- 2 Anaesthetic gel such as Instillagel® (lidocaine 2% and chlorhexidine gluconate solution 0.25%) used with Instillaquill® applied on the ectocervix and directly into the endocervical canal takes up to 5 minutes to work. Therefore I rely on its lubricant properties in enhancing ease of uterine instrumentation.
- 3 Topical application of lidocaine ointment (5%) on the ectocervix.

There is a lack of randomised controlled trials investigating the use of topical or intracervical anaesthesia during IUD/IUS insertions.

Methods used to aid clinicians in dilating the cervix or if resistance is encountered are listed below.

- 1 A plastic disposable graduated uterine sound and dilator is available from Durbin Sales. Dilatation up to 5.5 mm can be achieved with this disposable plastic instrument that has a graduated cervical dilator at one end and a sound at the other end. It is marked at 1 cm intervals, and the dilator end is tapered with gradual increase in width to 5.5 mm and has a gentle curve. In my experience it is easy to use compared to the metal Hegars dilators.
- 2 Vaginal use of misoprostol (200 µg) inserted 3 hours prior to IUD/IUS insertion softens the cervix. This may cause some vaginal bleeding and cramps, and due to the risk of teratogenicity should be used during a period or a reliable method of contraception should be advised during that cycle.

Previous Caesarean section is a risk factor for perforation.² Risk of perforation is directly proportional to the degree of difficulty encountered during insertion, clinician experience and technique.

I can foresee that these potential difficult cases will be referred to specialist clinics or will be done by experienced practitioners.

I share Dr Draper's concerns about trainees who would have to learn in this environment and the need for more training sessions to enable them to achieve adequate skills.

Manju Navani, MFSRH, MRCOG
Associate Specialist, Stockport Primary Care Trust, Contraception and Sexual Health, Adswood Clinic, Stockport, UK.
E-mail: manju.navani@yahoo.co.uk

References

- 1 Draper IB. Difficult IUD insertions [Letter]. *J Fam Plann Reprod Health Care* 2008; **34**: 67.
- 2 Chi I, Feldbum PJ, Rogers SM. IUD-related uterine perforation: an epidemiological analysis of a rare event using an international data set. *Adv Contracept Del Systems* 1984; **5**: 123–130.

Reply

I agree with Dr Navani that the plastic disposable sound and dilator seems more satisfactory than traditional metal dilators. A technique I use with Instillagel® that seems to make this method of local anaesthetic more effective is to keep the speculum in place for the 5 minutes after applying it (with due apologies to the woman for the indignity!) so the cervix is bathed in the gel that pools in the jaws of the speculum. I was interested to read of the use of misoprostol in this situation, which I was not aware of.

Some innovative ideas have obviously evolved in response to this problem. Perhaps a future article for the journal could be a summary of these, seeing as I am obviously not alone in experiencing the problem.

Isabel B Draper, MRCGP, FFSRH
General Practitioner, Whitehall Medical Practice, Rugby, UK.
E-mail: IBD@doctors.org.uk

Reference

- 1 Navani M. Difficult IUD insertions [Letter]. *J Fam Plann Reprod Health Care* 2008; **34**: 135.

Removal of copper-bearing IUDs in asymptomatic patients

We read with interest the case report regarding the migration of an intrauterine device (IUD) in an asymptomatic woman post-insertion.¹ We have also recently had a case of IUD migration in an asymptomatic patient. She had a copper-bearing IUD inserted 10 weeks after normal vaginal delivery that was uncomplicated. The patient had been fully counselled regarding contraceptive choices, and was still breastfeeding at this time. As per the World Health Organization *Medical Eligibility Criteria for Contraceptive Use* (WHOMEC), the IUD was inserted more than 4 weeks postpartum.²

A review appointment 2 months later found that the strings of the IUD were absent. A pelvic ultrasound demonstrated that the IUD was no longer in the uterine cavity and an abdominal X-ray confirmed the presence of the IUD in the abdominal cavity.

Following usual clinical practice guidelines,³ laparoscopy was performed to extract the device. This occurred 4 months after initial insertion. Figures 1 and 2 show that the IUD was already encased in adhesions. Fortunately, this IUD was clearly visualised at the time of the procedure, and was easily retrieved via the laparoscopic approach (Figure 3). The patient herself had no clinical symptoms, and chose to have another copper-containing IUD inserted during the same procedure. She was reviewed again 6 weeks postoperatively having had her first menses postpartum without issues.

Markovitch *et al.* have argued that extrauterine IUDs need not be surgically removed in well patients. Their series of three patients had no adhesions. Two were asymptomatic, and one had lower abdominal pain. They speculate that adhesions may be perhaps caused by the initial inflammatory or infective process and may not progress. They also contend that the effects of the copper in IUDs are not definitively proven, and that surgery may also inflict greater harm.⁴

However, the patient described by Jatti *et al.* had a significant complication with a peritoneal abscess, and yet was relatively well.¹ In our patient, the IUD was already enveloped in adhesions despite the short time duration within the pelvic cavity.

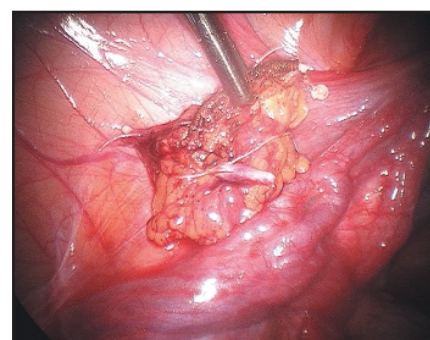
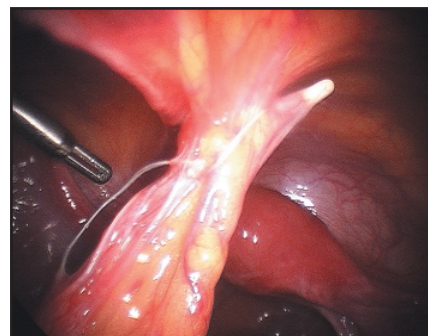
Markovitch *et al.* suggested a conservative approach in asymptomatic patients pending results from research in animal models.⁴ However, previous animal studies have demonstrated that adhesions from copper-bearing devices can cause severe adhesions involving necrosis and have greater fibrotic reactions than non-medicated IUDs.^{5,6}

We believe that the potential of complicated sequelae arising from the presence of a copper-bearing IUD outweigh the benefits of a conservative approach. Minimally invasive methods to remove translocated IUDs are becoming the mainstay approach, with alternatives for locating the IUD that is not easily visualised in order to reduce conversion to laparotomy, thus decreasing patient morbidity.⁷ Extrauterine IUDs should therefore be removed even in the asymptomatic patient.

Laura Lee, MBBS
Registrar, Department of Obstetrics and Gynaecology, Royal Women's Hospital, Melbourne, Australia

Alex Ades, MD, FRANZCOG
Consultant Obstetrician and Gynaecologist, Department of Obstetrics and Gynaecology, Royal Women's Hospital, Melbourne, Australia

W Catarina Ang, MBBS, FRANZCOG
Consultant, Gynaecologist and Laparoscopic Surgeon, Department of Obstetrics and Gynaecology, Royal Women's Hospital, Melbourne, Australia.
E-mail: catarina.ang@rw.org.au



Figures 1 and 2 The intrauterine device is cased in adhesions 4 months following initial insertion

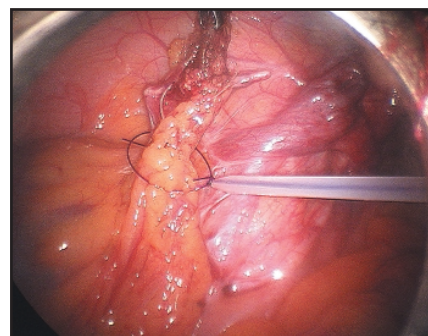


Figure 3 Removal of the intrauterine device using a laparoscopic approach

References

- 1 Jatti J, James S, James MC. Peritoneal abscess resulting from a translocated copper intrauterine device. *J Fam Plann Reprod Health Care* 2007; **33**: 57–58.
- 2 World Health Organization (WHO). *Medical Eligibility Criteria for Contraceptive Use* (WHOMEC). Geneva, Switzerland: WHO, 2000.
- 3 Faculty of Family Planning and Reproductive Health Care Clinical Effective Unit. FFRHC Guidance (January 2004). The copper intrauterine device as long-term contraception *J Fam Plann Reprod Health Care* 2004; **30**: 29–42.
- 4 Markovitch O, Klein Z, Gidoni Y, Holzinger M, Beyth Y. Extrauterine mislocated IUD: is surgical removal mandatory? *Contraception* 2002; **66**: 105–108.
- 5 Avi A, David MP, Pautzner D. The peritoneal reaction to the translocated copper intrauterine device in women and female rats. *Fertil Steril* 1983; **39**: 193–196.
- 6 Prevo M, Langston JB, Pharriss BB, Reno FE, Sheldon JJ. Local effects of intrauterine contraceptives placed within the peritoneal cavities of rabbits. *J Reprod Med* 1980; **24**: 32–38.
- 7 Oliver R, Jagadeesan P, Coker A. Laparoscopically assisted retrieval of lost IUCD/foreign bodies: a novel locating technique with fluoroscopic image intensifier. *Surg Laparosc Endosc Percutan Tech* 2007; **17**: 303–306.

Reply

We welcome the response by Lee *et al.*¹ which is a valuable contribution towards the management of translocated intrauterine devices (IUDs).

Lee *et al.* referred to the series of three cases described by Markovitch *et al.*² These patients did not develop any complications resulting from the translocated IUD. Markovitch *et al.* clearly describe the circumstances under which conservative management of translocated IUDs is possible and also express the need for additional study of peritoneal reactions.

The WHO³ and Faculty of Sexual and Reproductive Healthcare⁴ guidelines recommend removing the IUD, particularly the copper ones, as soon as is reasonably possible. The problem with not following these guidelines is the unpredictability of the migration of the IUD and the associated outcome.

Beard⁵ describes a case history of a patient using a Copper-7[®] IUD who remained asymptomatic for 2 years despite the device being translocated to the sigmoid colon without any evidence of intra-abdominal adhesions or sepsis.

The remote possibility of catastrophic events cannot be ruled out. Robinson⁶ describes an asymptomatic patient at serious risk from catastrophic rupture of the superior mesenteric artery by a translocated Copper-7 device.

Avni *et al.*⁷ studied the peritoneal reaction to copper devices in female albino rats. They found that 90% of the rats in the copper device group developed severe adhesions and consequently they recommended removal to minimise the harmful effects of copper. It is unclear to what extent these findings can be applied to humans.

In the absence of a tool to assess the risk, we recommend adhering to the WHO and Faculty of Family Planning guidelines.

We would welcome further discussion of this topic.

Jyoti Jatti, MD, DFSRH

Specialist Registrar, University Hospital, Coventry, UK. E-mail: jyotijatti@yahoo.co.uk

Mark C James, MD, MRCOG

Consultant, Department of Obstetrics and Gynaecology, Gloucestershire Royal Hospital, Gloucester, UK

References

- 1 Lee L, Ades L, Ang WC. Removal of copper-bearing IUDs in asymptomatic patients [Letter]. *J Fam Plann Reprod Health Care* 2008; **34**: 135–136.
- 2 Markovitch O, Klein Z, Gidoni Y, *et al.* Extrauterine mislocated IUD: is surgical removal mandatory? *Contraception* 2002; **66**: 105–108.
- 3 World Health Organization (WHO). *Medical Eligibility Criteria for Contraceptive Use*. Geneva, Switzerland: WHO, 2000.
- 4 Faculty of Family Planning and Reproductive Health Care Clinical Effective Unit. FFRHC Guidance (January 2004). The copper intrauterine device as long-term contraception *J Fam Plann Reprod Health Care* 2004; **30**: 29–42.
- 5 Beard RJ. Unusual presentation of translocated

intrauterine contraceptive device. *Lancet* 1981; **1**(8224): 837.

- 6 Robinson RE. Copper intrauterine devices in the abdomen. *BMJ* 1978; **2**(6144): 1088.
- 7 Avni A, David MP, Pautzner D. The peritoneal reaction to the translocated copper intrauterine device in women and female rats. *Fertil Steril* 1983; **39**: 193–196.

Training for the LoC IUT

I read Dr Siddiqui's letter¹ in the January 2008 issue of the Journal written in response to my letter² in the October 2007 issue. It was unfortunate that Dr Siddiqui's letter was submitted too close to the press deadline to allow sufficient time for me to respond to her letter in the same issue of the Journal.

Dr Siddiqui does not seem to have understood my point. I was not saying that we should not fit copper intrauterine devices (IUDs) and I am happy to do so if women request them. My point, which Dr Siddiqui accepts, was that most general practitioners (GPs) will only fit the intrauterine system (IUS) (Mirena[®]) and if we insist that they must fit a copper IUD to obtain their Letter of Competence (LoC) then most of them will not be able to train. Most general hospitals do not have the facility to do all IUD fitting and many family planning clinics are under threat. We do need GPs to fit IUDs, both for contraception and also for the treatment of menorrhagia. If we do not allow them to obtain the LoC then they will stop fitting IUDs/IUS. This will not benefit patients. It is difficult for doctors who wish to train to obtain the necessary experience; we do not need to make it more difficult.

Beth Devonald, MBBS, MRCGP

Associate Specialist in Sexual Health and Reproductive Health Care, Lincoln, UK. E-mail: devonald@btinternet.com

References

- 1 Siddiqui F. Training for the LoC IUT [Letter]. *J Fam Plann Reprod Health Care* 2008; **34**: 67–68.
- 2 Devonald B. Training for the LoC IUT [Letter]. *J Fam Plann Reprod Health Care* 2007; **33**: 288–289.

Localisation of non-palpable implants

I read the article by Mansour *et al.*¹ on methods of accurate localisation of non-palpable subdermal implants in the January 2008 issue of the Journal with great interest. I agree that alongside my own growing experience of implant insertions follows the request for removals. Identifying the insertion errors and unusual anatomical sitings of the implant was particularly interesting. The authors' suggestion that some experts use local anaesthetic to separate the tissue planes was a good tip. This has helped separate tissue planes thus facilitating less painful subcutaneous removal. I also liked the simple advice of asking the patient where the implant was inserted and seeing the scar.

All in all a very valuable piece of reading! Thank you.

Melanie Abeysondera, MBBS, BSc

GP Registrar, Lawley Medical Practice, Farriers Green, Lawley Bank, Telford TF4 2LL, UK

Reference

- 1 Mansour D, Fraser IS, Walling M, Glenn D, Graesslin O, Egarter C, *et al.* Methods of accurate localisation of non-palpable subdermal contraceptive implants. *J Fam Plann Reprod Health Care* 2008; **34**: 9–12.

Reply

We were pleased to hear that Dr Abeysondera¹ found our article on localisation of non-palpable subdermal implants² to be of some value. This article arose out of extensive discussion within a group of experts who have each independently developed their own ways of locating and removing implants that are not palpable. The experts have tried to ensure that most of their practical tips on localisation were highlighted in this article.

Fortunately, deep insertions of Implanon[®] are uncommon, but all family planners, general practitioners, gynaecologists and general surgeons need to be aware that they may occasionally be faced with a patient requiring removal of an implant which cannot be palpated. Knowledge that an effective recommended strategy for management exists (and that specific expert advice is available, if required) should help to minimise some of the challenges encountered during difficult localisation and removal.

Dr Abeysondera may also be interested to see the review appearing in this issue of the Journal, which comes from the same group of experienced colleagues and specifically addresses the issue of removal of deep implants.³ We hope that this will also help to minimise complications sometimes encountered in attempts at these procedures.

Diana Mansour, FRCOG, FFSRH

Consultant in Community Gynaecology, Contraception and Sexual Health Service, Newcastle upon Tyne Primary Care Trust, Graingerville Clinic, Newcastle upon Tyne, UK. E-mail: Diana.Mansour@newcastle-pct.nhs.uk

Ian S Fraser, MD, FRANZCOG

Professor in Reproductive Medicine, Department of Obstetrics and Gynaecology, University of Sydney, Sydney, Australia

References

- 1 Abeysondera M. Localisation of non-palpable implants [Letter]. *J Fam Plann Reprod Health Care* 2008; **34**: 136.
- 2 Mansour D, Fraser IS, Walling M, Glenn D, Graesslin O, Egarter C, *et al.* Methods of accurate localisation of non-palpable subdermal contraceptive implants. *J Fam Plann Reprod Health Care* 2008; **34**: 9–12.
- 3 Mansour D, Walling M, Glenn D, Egarter C, Graesslin O, Herbst J, *et al.* Removal of non-palpable etonogestrel implants. *J Fam Plann Reprod Health Care* 2008; **34**: 89–91.

Implanon insertion in Zimbabwe

Recently in a family planning session, a 32-year-old Zimbabwean female presented for an Implanon[®] removal. The patient was insistent that she had had Implanon inserted and that the procedure had involved two rods and that she had been advised that this would last for 5 years. On palpation, two rods could be felt in different planes in the left upper arm but it was difficult to decipher whether these were one rod divided in two or two separate rods. Upon removal, they were found to be two separate intact Implanon devices.

On further enquiry from the patient, we were advised that it was common practice for two rods to be inserted at a medical practice in Zimbabwe, and that patients had been advised that duration was 5 years. The patient had not experienced any adverse effects and had decided to have the Implanon removed so that she could become pregnant.

It would be interesting to know whether the above is a true representation of Implanon insertion in Zimbabwe and, if so, whether this is an indication of training needs or whether there appears to be a misconception that two rods must in combination provide greater contraceptive cover than one, in light of previous use of Norplant[®].

We would be grateful for any feedback from readers.

Sukhi Dhesi, MBBS, MRCGP

General Practitioner and Family Planning Doctor, Family Planning Clinic, Brunswick Clinic, St Mary's Lodge, Leamington Spa CV31 1JN, UK.

Madeline Davis, MBBS, MRCGP

General Practitioner and Family Planning Doctor, Family Planning Clinic, Brunswick Clinic, Leamington Spa, UK