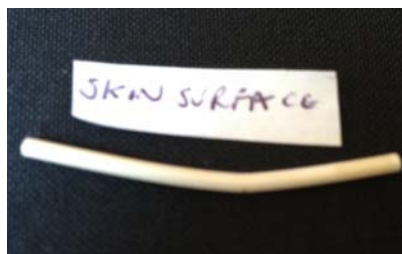


## Removal of a fractured Nexplanon<sup>®</sup>

I was interested to read the report by Pickard and Bacon<sup>1</sup> of a broken Implanon<sup>®</sup> (subdermal progestogen implant) following known trauma to the arm, where the patient had concerns as it felt different under the skin. By contrast, I have come across a fractured Nexplanon<sup>®</sup> for which the patient could not recall any injury.

A 17-year-old woman who had the implant inserted 14 months previously attended clinic to discuss and book its removal and change of method. She had had troublesome bleeding, present since 2 months after insertion, which settled with each 3-month supply of the combined oral contraceptive pill (COC) and then recurred. At that consultation the implant was not palpated but the woman did not report any problems with the feel of the implant. She was started on the COC in advance of the booked removal appointment, which was 6 weeks later.

When she returned for the removal she said that the implant “felt like it had a dip in it”, which she had noticed 2 weeks previously. The implant did feel as if there was a difference along its length with regard to the depth below the skin. On removal via the pop-out procedure from the distal end it was found to be curved to about 10° roughly halfway along its length, with a noticeable breach in the convex surface of the curvature (Figure 1). The patient said she



**Figure 1** The implant following removal showing the obvious curvature roughly halfway along its length, with a noticeable breach in the convex surface of the curvature.

had not had any trauma to the arm prior to noticing the difference in shape. As discussed in Pickard and Bacon's report,<sup>1</sup> there may be a reduction in contraceptive effect if the implant is fractured, and this may be because of the larger surface area from which the progestogen is released. Fortunately in this case the woman was already protected by another contraceptive method at the time that she noticed the change in the implant. There remains the question as to how this curvature and non-continuity of the rod occurred, and I wonder if any other clinicians have observed anything like this.

**Alyson Elliman**, FFSRH, MIPM

Consultant in Sexual and Reproductive Health,  
Croydon Health Services NHS Trust, Croydon, UK;  
alyson.elliman@croydonhealth.nhs.uk

**Competing interests** None.

*J Fam Plan Reprod Health Care* 2013;**39**:66–67.  
doi:10.1136/jfprhc-2012-100491

## REFERENCE

- 1 Pickard S, Bacon L. Persistent vaginal bleeding in a patient with a broken Implanon®. *J Fam Plann Reprod Health Care* 2002;**28**:207–208.